



California Pacific
Medical Center

A Sutter Health Affiliate

Community Based, Not For Profit

Cyanoacrylate Treatment of Gastric Varices

INTERVENTIONAL ENDOSCOPY SERVICE

At California Pacific Medical Center we are committed to bringing new and advanced diagnostic tools, medical treatments and surgical options to the physicians we serve and the patients they care for. Through this procedure profile, our physicians illustrate actual medical situations that provide you with a window into their practice of diagnosis, treatment and patient follow-up.

For patient referrals:
(888) 637-2762

www.cpmc.org/ies

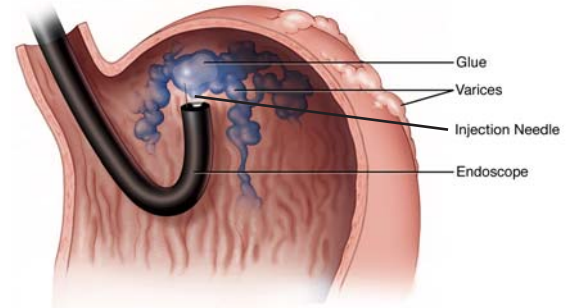
Gastric variceal bleeding

Variceal bleeding is a devastating complication of portal hypertension. One third of patients die after the first bleed. Many factors contribute to the high mortality and morbidity. Bleeding not only precipitates hemodynamic instability, but also necessitates aggressive fluid resuscitation and blood product replacement that can result in multiple secondary complications such as ascites, jaundice, renal failure, and infection. Worsening of compromised hepatic function, coagulopathy, and encephalopathy add to the poor prognosis.

Although varices can develop anywhere along the gastrointestinal tract, they are most common in the esophagus and stomach. Gastroesophageal varices develop in 50% to 60% of cirrhotic patients and approximately one-third of them will experience an episode of variceal hemorrhage within two years of varices diagnosis. Bleeding gastric varices account for roughly 10% to 15% of all variceal bleeds.

How do gastric varices differ from esophageal varices?

Esophageal and gastric varices differ in their morphology, pathophysiology, and natural history. While gastric varices bleed less frequently than esophageal varices, the severity of bleeding and associated mortality is greater. Compared with esophageal varices, gastric varices are larger, more extensive, and lie deeper in the submucosa. As a result, standard endoscopic treatments for esophageal varices, including band ligation and sclerotherapy, are largely ineffective for gastric varices.



Cyanoacrylate is delivered endoscopically into gastric varices through a standard injection catheter.

Classification of gastric varices

Gastric varices are classified depending on their relationship to esophageal varices and their location within the stomach. Gastroesophageal varices extend across the gastroesophageal junction either along the lesser curve or the greater curve. Isolated gastric varices lack continuity with esophageal varices and usually occur in the fundus. Morphologically, gastric varices can be further divided into three types based on their endoscopic appearance: single polyp-like structure; conglomerate of polypoid varices; and serpiginous rugae-like vessels. Typical fundal varices are large polypoid structures and pose the greatest challenge for treatment (*See cases 1-3*).

Ectopic varices include duodenal varices (*See case 4*), which occur most commonly in the bulb. They can be flat, making detection difficult.

What are the treatment options?

In the setting of active bleeding, pharmacologic therapy and balloon tamponade can be used as temporary measures to achieve hemostasis for short periods of time. Definitive treatment requires either the endoscopic obliteration of varices or the correction of underlying portal

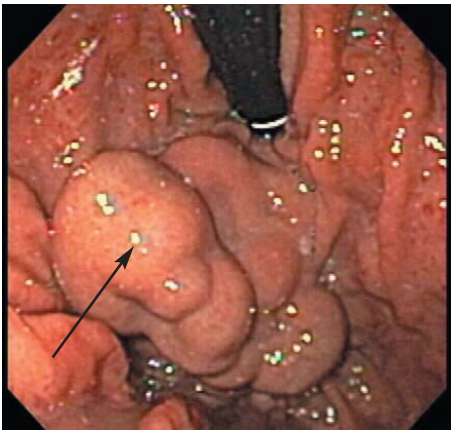
continued on back page

case studies

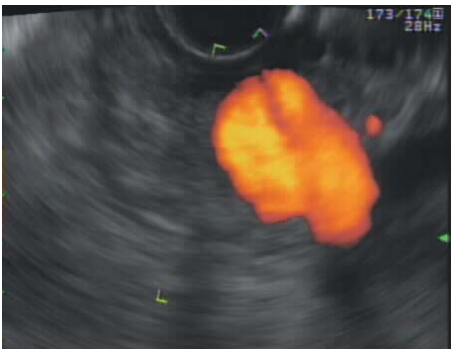1: Recurrent gastrointestinal bleeding

Case Overview

A 60-year-old man with cirrhosis secondary to alcoholic liver disease presented with a history of multiple gastrointestinal bleeds over a three-year period. The patient had a history of both esophageal and gastric varices and had undergone multiple episodes of esophageal variceal band ligation. Endoscopic evaluation prior to his referral to California Pacific Medical Center revealed a large gastric varix with evidence of portal hypertensive gastropathy. The patient was not a candidate for a TIPS procedure due to a portal vein thrombosis and was therefore referred for cyanoacrylate therapy.



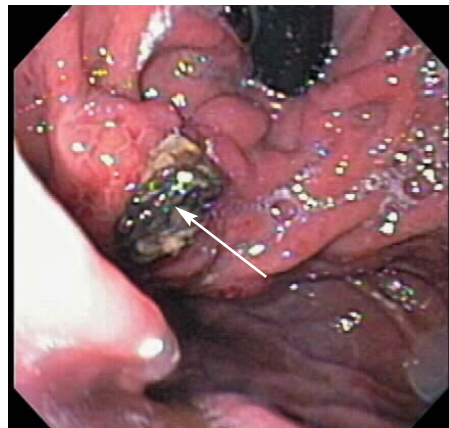
Case 1. Large multilobulated gastric varix in the fundus.



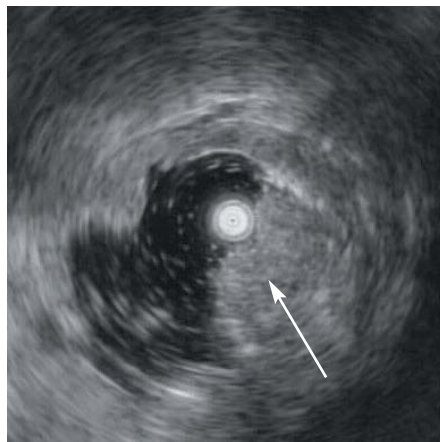
Case 1. Endoscopic ultrasound showing Doppler flow in large varix.

Treatment

The patient was noted to have a massive multilobulated gastric varix and underwent two separate injections of cyanoacrylate glue. Over the following twelve months repeat endoscopies revealed obliteration of the gastric varix with an obvious glue plug extruding from the injection site. Endoscopic ultrasound confirmed the obliteration of the varix lumen.



Case 1. Obliterated fundal varices with glue plug extruding from the injection site.



Case 1. Endoscopic ultrasound showing obliteration of the varix lumen.

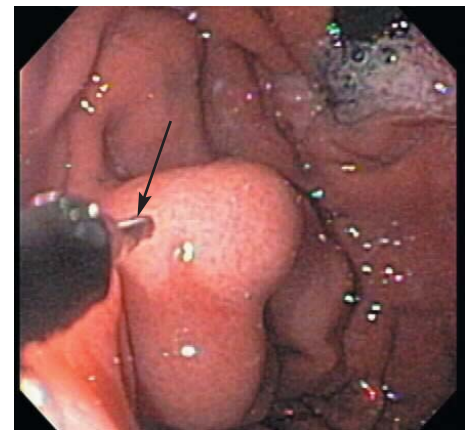
Outcome

More than one year after the procedure the patient has had no further gastrointestinal bleeding. The patient developed no complications from the procedure and is feeling well.

2: Gastric varices with portal and splenic vein thrombosis

Case Overview

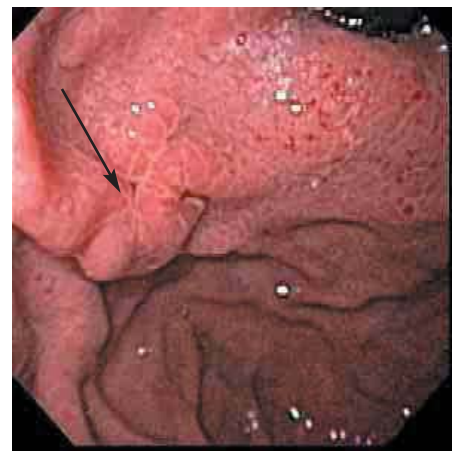An 80-year-old male with a history of multiple endocrine neoplasia type 1 presented to an outside hospital with burgundy stool. He had a history of gastric varices secondary to thrombosis of the portal and splenic veins. The patient was referred to the Interventional Endoscopy Service for glue injection.



Case 2. Large gastric varix with needle (arrow) in position for injection.

Treatment

The large gastric varix was obliterated with a single injection of cyanoacrylate glue.



Case 2. Nine months later the varix is completely obliterated and replaced by scar tissue.

Outcome

Follow-up endoscopies over the following nine months confirmed

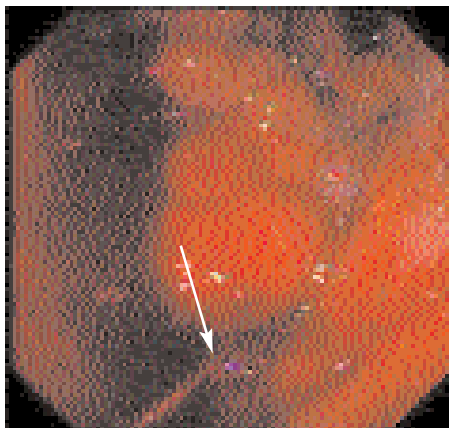
case studies

varix obliteration. The patient has had no further gastrointestinal bleeding and is scheduled for one more endoscopic follow up.

3: Acute gastric variceal bleeding after surgical shunt

Case Overview

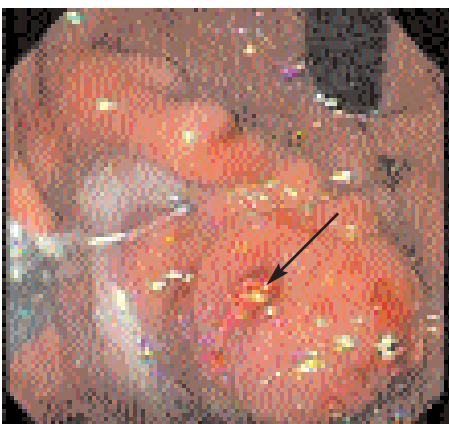
A 71-year-old male with cryptogenic cirrhosis and hepatocellular carcinoma was transferred from an outlying hospital with acute GI bleeding. He underwent portal decompressive surgery one year earlier for variceal bleeding. Urgent endoscopy revealed a large multilobulated fundal varix with active spurting.



Case 3. Large fundal varix with active hemorrhage.

Treatment

Glue was injected close to the bleeding point. Active bleeding ceased, leaving a glue plug at the bleeding site.



Case 3. Same varix after glue injection. Note glue extruding from injection site.

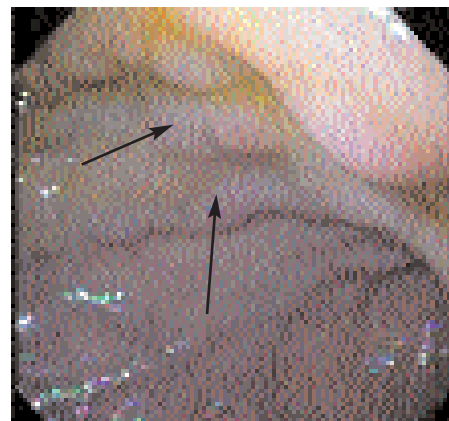
Outcome

Over the subsequent month the patient did well without further bleeding. Unfortunately, he missed his follow-up endoscopy at one month and did not undergo additional injections to obliterate all of his large fundal varices. The patient moved back to Southern California and died after a massive recurrent GI bleed. The case illustrates the importance of obliterating all visible gastric varices.

4: Bleeding duodenal varices

Case Overview

A 42-year-old male with a history of necrotizing biliary pancreatitis complicated by splenic vein thrombosis presented with episodic transfusion-dependent melena. Multiple upper and lower endoscopies, RBC tagged scans, and small bowel radiographs were unrevealing of a bleeding source. Capsule endoscopy was performed, but the capsule failed to exit the stomach. A follow-up endoscopy suggested possible duodenal varices.

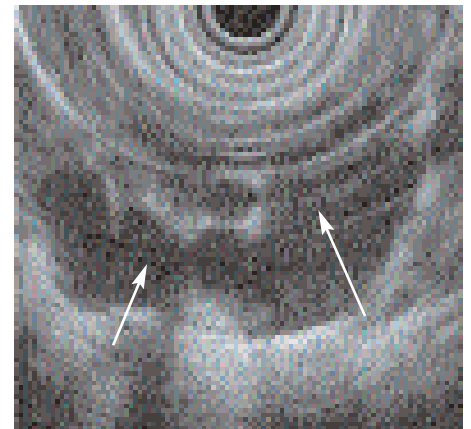


Case 4. View of duodenal bulb with serpiginous varices.

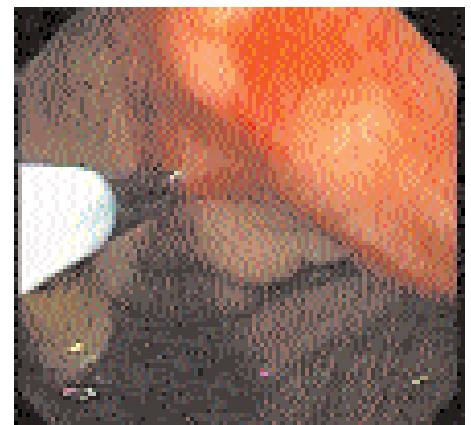Treatment

Upper endoscopy showed serpiginous areas of mucosal elevation in the duodenal bulb that were "soft" on palpation. Endoscopic ultrasonography confirmed duodenal varices.

Cyanoacrylate glue was injected to obliterate the varices.



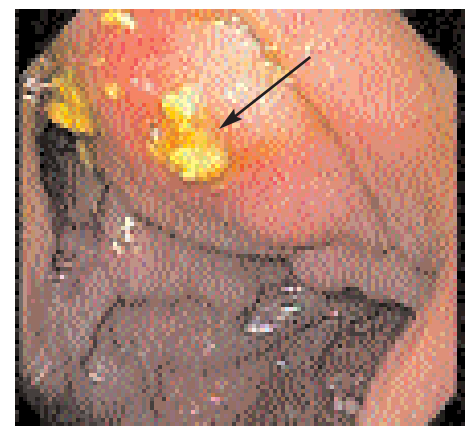Case 4. Endoscopic ultrasound showing a convolute of duodenal varices.



Case 4. Injection of cyanoacrylate glue.

Outcome

Follow-up endoscopy one month later showed glue extruding from the site of previous glue injection. The varices were "hard" to instrumental palpation. No further bleeding was observed over the next six months.



Case 4. Glue extruding from the injection site one month later.

Cyanoacrylate Treatment of Gastric Varices

continued from front page

hypertension. The latter is accomplished with a shunt procedure, which may be performed by an open surgical or radiologic transvenous portosystemic shunt (TIPS) approach. TIPS procedure is less invasive than a surgical shunt and therefore generally preferred over a surgical shunt. The major drawbacks of TIPS are a high rate of encephalopathy, worsening of liver function, and the propensity for the TIPS to occlude due to thrombosis, necessitating re-intervention. Some patients are not candidates for TIPS due to the presence of portal vein thrombosis or a diminutive portal vein.

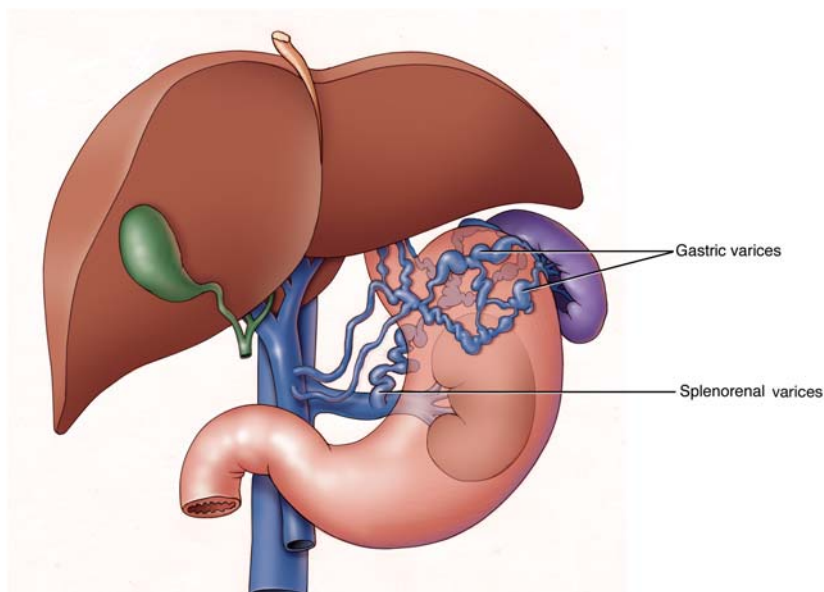
How does cyanoacrylate glue treatment work?

Cyanoacrylate is a liquid substance with a consistency of water that transforms into a solid state when added to a physiological medium such as blood. When instilled into a varix using the standard method of intravariceal injection, the glue undergoes an instantaneous polymerization reaction and hardens to a rock hard substance, thereby plugging the lumen of the varix. This enables rapid hemostasis of active bleeding and prevents rebleeding.

How is glue injection performed?

A therapeutic gastroscope with a large working channel is used for injection. Variceal injection is performed with a 23-gauge disposable sclerotherapy needle. The varix is punctured under direct visualization and approximately 1 cc of the glue is injected intravariceally. After injection, the patency of the varix is assessed with blunt catheter palpation and additional glue injected until the varices are obliterated.

Fundic gastric varices



Gastric fundal varices form, secondary to diffuse or segmental portal hypertension, resulting in congestion and dilation of the short and posterior gastric veins. Collaterals may drain to the inferior vena cava through a gastro-renal shunt.

How effective is cyanoacrylate treatment?

Numerous studies from around the world with over 1,000 treated patients have reported control of active variceal bleeding in 93% to 100% of patients with rates of recurrent bleeding around 10%.

What are the risks?

Cyanoacrylate compounds are routinely used in different medical and surgical subspecialties for embolization of aneurysms, arteriovenous malformations and fistulae, and as a wound or tissue adhesive. The safety profile of cyanoacrylate glue for varix obliteration is excellent. A minority of patients develop transient fever and pain after injection. There have been rare case reports of complications related to embolization, which include cerebral stroke and pulmonary embolism. Visceral fistulas have also been reported, probably due to misguided injections.

Should gastric varices be treated prophylactically?

The risk of gastric variceal hemorrhage depends on multiple factors including varix size, presence of “red signs,” and the underlying degree of liver disease. We prophylactically treat patients with varices >1 cm with either red signs or advanced liver disease (Child B or C). The one-year risk of bleeding in a Child C cirrhotic with red marks on a large fundal varix is estimated at 65%.

For more information

Please contact the Interventional Endoscopy Service at **(415) 600-1151** or email Dr. Binmoeller at **binmoek@sutterhealth.org**

Kenneth E. Binmoeller, M.D.
Medical Director
Interventional Endoscopy Service

www.cpmc.org/ies