







Article

Article Outline

-  **2 Iconography**
-  **Access to the text (HTML)**
-  **Access to the PDF text**
-  **Print**
-  **Recommend this article**
-  **Save as favorites**

Service d'aide à la décision clinique


Free Article !


Gastroentérologie Clinique et Biologique
Volume 32, n° 11
pages 926-930 (novembre 2008)
 Doi : 10.1016/j.gcb.2008.07.009

Acute fatal pulmonary embolism during cyanoacrylate injection in gastric varices

Embolie pulmonaire fatale au décours d'une injection de varices gastriques par cyanoacrylate

A.-M. Marion-Audibert ^{a, *}, M. Schoeffler ^b, F. Wallet ^b, S. Duperret ^b, J.-Y. Mabrut ^c, B. Bancel ^d, D. Pere-Verge ^a, L. Wander ^a, J.-C. Souquet ^a

^a Service d'hépatogastroentérologie, hôpital de la Croix-Rousse, 103, grande rue de la Croix-Rousse, 69317 Lyon cedex 04, France

^b Service de réanimation chirurgicale, hôpital de la Croix-Rousse, 103, grande rue de la Croix-Rousse, 69317 Lyon cedex 04, France

^c Service de chirurgie digestive, hôpital de la Croix-Rousse, 103, grande rue de la Croix-Rousse, 69317 Lyon cedex 04, France

^d Service d'anatomie et cytologie pathologiques, hôpital de la Croix-Rousse, 103, grande rue de la Croix-Rousse, 69317 Lyon cedex 04, France

* *Corresponding author.*

► Summary

We report a case of massive pulmonary embolism during cyanoacrylate glue endoscopic injection in a patient with gastric varices from portal hypertension. A review of the literature and results in an animal model show the physiopathology and risk factors associated with this endoscopic procedure.

The full text of this article is available in PDF format.

► Résumé

Nous rapportons le cas d'un patient cirrhotique présentant une hypertension portale compliquée de varices gastriques fundiques, traitées endoscopiquement par injection de cyanoacrylate. Au décours immédiat du geste, le patient présenta une défaillance circulatoire en rapport avec une embolie pulmonaire massive, entraînant son décès. La revue de la littérature et l'expérience réalisée chez l'animal ont permis de préciser les mécanismes physiopathologiques et les facteurs de risque de complication associés à l'injection de colle de varices gastriques.

The full text of this article is available in PDF format.

Outline

[Masquer le plan](#)

- Introduction**
- Case report**
- Discussion**
- Conclusion**

Top of the page - Article Outline

► Introduction

The rupture of esophagogastric varices is one of the major causes of hemorrhage in patients with portal hypertension, a complication with a high mortality rate. Approximately 20% of patients with portal hypertension develop gastric varices. During bleeding episodes, the management of gastric varices is difficult because hemostatic procedures such as band ligation or sclerosis are less effective in this setting [1, 2, 3, 4, 5]. Variceal injection involves the intravariceal injection of occluding material such as cyanoacrylate. This glue acts as a tissue adhesive that polymerizes on contact with blood leading to a clot that obstructs the varices. Injection of varices with cyanoacrylate has been associated with various complications such as hemorrhages, infections, ulcerations or embolic events [7]. The presence of a massive perigastric or perisplenic portosystemic shunt is a major risk factor of embolism and should be systematically screened for.

We describe a case of fatal pulmonary embolism during cyanoacrylate injection for bleeding in gastric varices. The case is discussed in relation to the literature.

Top of the page - Article Outline

► Case report

A 77-year-old patient, with a medical history of alcoholic cirrhosis and portal hypertension with a Child Pugh score B, was referred to our hospital for the treatment of gastric varices. There were no other existing diseases, including heart failure or encephalopathy. Fifteen days before, the patient had presented with massive hematemesis revealing grade II fundic varices on gastric endoscopy; abdominal ultrasound showed a surrogate splenorenal shunt. After the initial medical treatment of this hematemesis with a vasoactive drug (somatostatin) without endoscopic treatment, he was admitted to our institution for prophylactic gastric varice injection under general anaesthesia. At admission, blood pressure was 110/75 mmHg. The electrocardiogram and chest radiography were normal. Endoscopic findings revealed gastric varices located in the fundus and extended esophageal varices (GOV 2) according to the Sarin classification [1]. Red signs were present in one of them. The endoscopic procedure included an injection of 1.5 ml *N*-butyl-2-cyanoacrylate (Glubran®; Gem Srl, Viareggio, Italy), diluted (50/50) with lipiodol (Andre Guerbet; Aulnay-sous-Bois; France) in the fundic varice with red signs. During the procedure, significant bleeding from the fundic varice required a second injection of 1.5 ml of Glubran®. A few minutes later, the patient experienced major circulatory instability and cardiac arrest. After prompt cardiopulmonary resuscitation, the patient recovered a spontaneous cardiac rhythm and was transferred to the ICU.

Despite infusions of adrenaline and blood, systolic arterial blood pressure remained below 50 mmHg.

Because of endoscopic failure and severe persistent bleeding associated with portal hypertension, the patient was transferred to the radiological room to perform an emergency transjugular intrahepatic portosystemic shunt (TIPS). Despite intensive reanimation, refractory cardiac arrest occurred and the patient died before TIPS could be attempted. A chest X-ray performed at that time showed multiple pulmonary emboli.

An autopsy was performed revealing on pathological examination numerous varicose veins predominantly in the lesser curvature of the stomach due to marked portal hypertension. One of these veins (the injected varice) was especially firm and filled with a brownish and granular material. This material was clearly different from the usual postmortem coagulum. Histopathological examination showed that this thrombus included exogenous, puzzle-shaped, optically clear material surrounding clusters of red blood cells, which corresponds histologically to dissolution of the sclerosing agent by inclusion procedures, leaving only its negative print on the slides. Macroscopic examination of the lungs revealed a severe distal embolism with the same brownish material in the pulmonary arteries especially in the left side (Figure 1). Furthermore, this material had the same histopathological appearance as that in the gastric varice. The comparison of pulmonary and gastric findings confirms the diagnosis of pulmonary embolism from the *N*-butyl-2-cyanoacrylate sclerotherapy induced gastric thrombus.

Figure 1



Figure 1.

Autopsic view: macroscopic aspect of left pulmonary parenchyma: brownish and granular exogenous material in a pulmonary artery (long arrow) differentiating itself from the usual postmortem coagulum (short arrow).

Vue autopsique : aspect macroscopique de parenchyme pulmonaire gauche : matière exogène brunâtre et granulaire dans une artère pulmonaire (longue flèche) se différenciant du caillot posthumortem habituel (flèche courte).

Zoom

Top of the page - Article Outline

► Discussion

Digestive hemorrhage is one of the most frequent and serious complications in patients with portal hypertension. Twenty percent of these patients may develop gastric or fundic varices. Although these varices are known to have a low risk of bleeding [1, 2, 3], digestive hemorrhage due to ruptured gastric varices has a high mortality rate because bleeding is more massive in this location. Moreover, in that particular case, haemostatic procedures such as band ligation or sclerotherapy are known to be more difficult to perform and less effective [4, 5].

Gastric varices may be injected with *N*-butyl-2-cyanoacrylate, a biological glue that almost instantly polymerizes on contact with ionized material such as plasmatic weak bases, blood or endothelium, forming a clot in the local vessel. A radiopaque substance (such as lipiodol) is used for control and visualization of the injected zone and is often mixed with glue. This dilution is associated with less rapid polymerization. Cyanoacrylate sclerotherapy is effective but there is a risk of several complications: general inflammation secondary to infection causing pain or fever [6, 7], local side effects of the injection such as ulcerations, necrosis, perforation or delayed dysphagia or stenosis [8, 9]. Infectious diseases such as mediastinitis or pneumonia may also occur [10, 11, 12]. However, the most important complication is recurrent hemorrhage due to endoscopic failure, secondary displacement of the clot or its exclusion from the injected vessel [13, 14]. Other rare but severe complications are caused by thromboembolic events either in the splenic, pulmonary, cerebral or coronary territories [15]. Pulmonary embolism is a rare but life-threatening complication of this procedure. In the 15 available studies reporting 1360 patients treated by cyanoacrylate glue, 14 pulmonary embolisms were reported (1%) with no fatalities [13, 14, 16, 17]. Two individual cases reported death following pulmonary embolism which occurred two and 37 days after the injection in a context of multiple organ failure. This case report is the first description of acute fatal pulmonary embolism immediately after cyanoacrylate injection.

The pathophysiology of a pulmonary embolism during endoscopic gastric varice glue injection is complex, and involves a portosystemic vascular shunt and especially a gastrosplenorenal shunt. A gastrosplenorenal shunt creates an anastomosis between the portal and systemic circulation, based on the reopening of embryonic vascular pathways between the splenic vein and the left renal vein [18]. This particular shunt passes through a vascular arch including the splenic polar superior vein, the posterior gastric vein and the collateral gastric vein. This arch is connected by a high flow to the splenic and the left renal vein by the cardio-tuberositarian vein. These high blood flow shunts may develop and carry clots or embolic material from injected varices and the portal circulation to the systemic venous flow, right heart and thus, the pulmonary circulation [19]. This pathophysiology explains the critical role of a high blood flow shunt. Another pathway may lead to pulmonary embolisms via the vena cava superior and the azygos vein but this seems to occur with esophageal rather than cardiac or gastric varices [20].

To confirm our hypothesis about the cause and pathophysiology of the death of this patient, we reproduced this sequence via a direct injection of the same cyanoacrylate and lipiodol mixture into the right cardiac cavities of an anesthetized pig through a Swan-Ganz catheter. The study was performed in a domestic pig from the institutional laboratory where animals were treated according to the guidelines of Claude-Bernard University Lyon-1 animal ethics committee. A transesophageal echocardiography (TEE) was performed during this procedure and cardiac output and pulmonary artery pressure were simultaneously recorded. A few seconds after the intrapulmonary artery injection of 3 ml of cyanoacrylate mixed with lipiodol, a sudden and dramatic increase in the pulmonary artery pressure was observed, associated with a decrease in cardiac output (Figure 2). At the same time, TEE showed a rapid dilation of the right heart cavities followed by right heart failure. This quickly led

to global heart failure, ventricular fibrillation and cardiac arrest. The animal died 5 minutes after Glubran® injection.

Figure 2

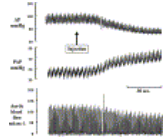


Figure 2.

Aortic pressure (AP), pulmonary arterial pressure (PAP), and aortic blood flow following Glubran® injection in the internal jugular vein of a pig. Corresponding echographic views are inserted.

Pression aortique (AP), pression artérielle pulmonaire (PAP) et flux sanguin aortique après injection de Glubran® dans la veine jugulaire interne d'un porc. Les échographies correspondantes sont insérées.

Zoom

This experiment confirms the pathophysiology of the systemic release of cyanoacrylate glue/lipiodol as a cause of acute and massive pulmonary embolism potentially resulting in acute right ventricle failure and death. The cause of death is the pulmonary embolism and not post-aggressive chemical acute respiratory distress syndrome (ARDS). Moreover, histological analysis confirms that the pulmonary embolism is due to a mechanical occlusion of the pulmonary arteries and not to secondary activation of coagulation.

The documents we report show that pulmonary embolism is secondary to the release of intravascular polymerized cyanoacrylate glue into the systemic circulation, leading to right heart failure.

Due to the potential severity of complications of variceal sclerosis, this technique should probably be reserved for selected patients [21]. Independent gastric varices, which have already bled, and bleeding gastric varices are the most beneficial indication. The haemostatic effect of endoscopic variceal ligation in gastric varices appears promising, but evidence is still limited. Recently, in a randomized trial, Tan et al. [5] showed that the efficacy of ligation for controlling active gastric variceal hemorrhage was not different from glue injection although glue injection was associated with a lower gastric variceal rebleeding rate. If glue injection is unavailable because there is no Histoacryl® or a lack of technical expertise, band ligation might be a temporary means to arrest active gastric variceal hemorrhages, especially GOV 1 and 2. The presence of a massive perigastric or perisplenic portosystemic shunt on abdominal ultrasound or CT-scan is a major risk factor of sclerosis induced pulmonary embolism and should be screened for. In this case, variceal sclerosis should probably be reconsidered and TIPS could be proposed because survival and the frequency of complications are similar in both procedures. TIPS has been shown to be more effective than glue injection in preventing rebleeding from gastric varices [22].

The treatment of a cyanoacrylate pulmonary embolism is a difficult issue. Indeed, anticoagulation or thrombolysis is ineffective. Therefore, except for symptomatic treatment, surgical embolectomy and/or extracorporeal cardiopulmonary assistance are the only therapeutic alternatives in case of a life threatening pulmonary embolism.

Top of the page - Article Outline

► Conclusion

This case report shows that massive pulmonary embolism may occur during endoscopic cyanoacrylate glue injection of gastric varices from portal hypertension. Although it is rare, this complication can be lethal. The risk factors must be evaluated before performing this procedure.

Top of the page - Article Outline

► References

- [1] Sarin S.K., Lahoti D., Saxena S.P., Murthy N.S., Makwana U.K. Prevalence, classification and natural history of gastric varices: a long-term follow-up study in 568 portal hypertension patients *Hepatology* 1992 ; 16 : 1343-1349 [cross-ref]
- [2] Yoshida T., Hayashi N., Suzumi N., Miyazaki S., Terai S., Itoh T., and al. Endoscopic ligation of gastric varices using a detachable snare *Endoscopy* 1994 ; 26 : 502-505 [cross-ref]
- [3] Kim T., Shijo H., Kokawa H., Tokumitsu H., Kubara K., Ota K., and al. Risk factors for hemorrhage from gastric fundal varices *Hepatology* 1997 ; 25 : 307-312 [cross-ref]
- [4] Park W.G., Yeh R.W., Triadafilopoulos G. Injection therapies for variceal bleeding disorders of the GI tract *Gastrointest Endosc* 2008 ; 67 : 313-323 [cross-ref]
- [5] Tan P.C., Hou M.C., Lin H.C., Liu T.T., Lee F.Y., Chang F.Y., and al. A randomized trial of endoscopic treatment of acute gastric variceal hemorrhage: *N*-butyl-2-cyanoacrylate injection versus band ligation *Hepatology* 2006 ; 43 : 690-697 [cross-ref]
- [6] Maluf-Filho F., Sakai P., Ishioka S., Matuguma S.E. Endoscopic sclerosis versus cyanoacrylate endoscopic injection for the first episode of variceal bleeding: a prospective, controlled, and randomized study in Child-Pugh class C patients *Endoscopy* 2001 ; 33 : 421-427 [cross-ref]
- [7] Chen W.C., Hou M.C., Lin H.C., Yu K.W., Lee F.Y., Chang F.Y., and al. Bacteremia after endoscopic injection of *N*-butyl-2-cyanoacrylate for gastric variceal bleeding *Gastrointest Endosc* 2001 ; 54 : 214-218 [cross-ref]
- [8] Kok K., Bond R.P., Duncan I.C., Fourie P.A., Ziady C., van den Bogaerde J.B., and al. Distal embolization and local vessel wall ulceration after gastric variceal obliteration with *N*-butyl-2-cyanoacrylate: a case report and review of the literature *Endoscopy* 2004 ; 36 : 442-446 [cross-ref]
- [9] Wahl P., Lammer F., Conen D., Schlumpf R., Bock A. Septic complications after injection of *N*-butyl-2-cyanoacrylate: report of two cases and review *Gastrointest Endosc* 2004 ; 59 : 911-916 [cross-ref]
- [10] Tan Y.M., Goh K.L., Kamarulzaman A., Tan P.S., Ranjeev P., Salem O., and al. Multiple systemic embolisms with septicemia after gastric variceal obliteration with cyanoacrylate *Gastrointest Endosc* 2002 ; 55 : 276-278 [cross-ref]
- [11] Verger P., Blais J., Gruau M., Haffaf Y. Retrogastric abscess secondary to gastric varices obturation with cyanoacrylate *Gastroenterol Clin Biol* 1998 ; 22 : 248-249
- [12] Turler A., Wolff M., Dorlars D., Hirner A. Embolic and septic complications after sclerotherapy of fundic varices with cyanoacrylate *Gastrointest Endosc* 2001 ; 53 : 228-230 [cross-ref]
- [13] Mumtaz K., Majid S., Shah H., Hameed K., Ahmed A., Hamid S., and al. Prevalence of gastric varices and results of sclerotherapy with *N*-butyl-2-cyanoacrylate for controlling acute gastric variceal bleeding *World J Gastroenterol* 2007 ; 13 : 1247-1251
- [14] Huang Y.H., Yeh H.Z., Chen G.H., Chang C.S., Wu C.Y., Poon S.K., and al. Endoscopic treatment of bleeding gastric varices by *N*-butyl-2-cyanoacrylate (Histoacryl®) injection: long-term efficacy and safety *Gastrointest Endosc* 2000 ; 52 : 160-167 [cross-ref]
- [15] Martins Santos M.M., Correia L.P., Rodrigues R.A., Lenz Tolentino L.H., Ferrari A.P., Della L.E. Splenic artery embolization and infarction after cyanoacrylate injection for esophageal varices *Gastrointest Endosc* 2007 ; 65 : 1088-1090 [cross-ref]

- [16] Dhiman R.K., Chawla Y., Taneja S., Biswas R., Sharma T.R., Dilawari J.B. Endoscopic sclerotherapy of gastric variceal bleeding with *N*-butyl-2-cyanoacrylate *J Clin Gastroenterol* 2002 ; 35 : 222-227 **[cross-ref]**
- [17] Habib S.F., Muhammad R., Koulaouzidis A., Gasem J. Pulmonary embolism after sclerotherapy treatment of bleeding varices *Ann Hepatol* 2008 ; 7 : 91-93
- [18] Wind P., Alves A., Chevallier J.M., Gillot C., Sales J.P., Sauvanet A., and al. Anatomy of spontaneous splenorenal and gastrosplenic venous anastomoses. Review of the literature *Surg Radiol Anat* 1998 ; 20 : 129-134 **[cross-ref]**
- [19] Kull E., Hernandez M., Richer J.P., Borderie C., Silvain C., Beauchant M. Severe pulmonary embolism after obturation of gastric varices with a butyl-cyanoacrylate and lipiodol combination *Gastroenterol Clin Biol* 1999 ; 23 : 1095-1096 **[inter-ref]**
- [20] DePuey E.G., Richards W.O., Millikan W.J., Henderson J.M. Scintigraphic detection of pulmonary embolization of esophageal variceal sclerosant *Endoscopy* 1988 ; 20 : 91-94 **[cross-ref]**
- [21] Consensus conference: complications of portal hypertension in adults (Paris, December 4-5, 2003). *Gastroenterol Clin Biol* 2004; 28 Spec No 2:B324-B334.
- [22] Lo G.H., Liang H.L., Chen W.C., Chen M.H., Lai K.H., Hsu P.I., and al. A prospective, randomized controlled trial of transjugular intrahepatic portosystemic shunt versus cyanoacrylate injection in the prevention of gastric variceal rebleeding *Endoscopy* 2007 ; 39 : 679-685 **[cross-ref]**

Top of the page – Article Outline

© 2008 Elsevier Masson SAS. All Rights Reserved.

[Contact](#) | [Help](#) | [Who are we?](#) | [© – Warnings](#) | [Editorial Policy](#) | [Advertising policy](#) | [Acknowledgements](#) | [Privacy Policy](#)

EM-CONSULTE.COM is registered at the CNIL, déclaration n° 1286925.

As per the Law relating to information storage and personal integrity, you have the right to oppose (art 26 of that law), access (art 34 of that law) and rectify (art 36 of that law) your personal data. You may thus request that your data, should it be inaccurate, incomplete, unclear, outdated, not be used or stored, be corrected, clarified, updated or deleted.

Personal information regarding our website's visitors, including their identity, is confidential.

The owners of this website hereby guarantee to respect the legal confidentiality conditions, applicable in France, and not to disclose this data to third parties.